

## Case report

# Crystalline deposits in the macula – tamoxifen maculopathy or macular telangiectasia?

Roshija Khanal Rijal, Chinmay Nakhwa, Manavi D Sindal  
Aravind Eye Hospital & Postgraduate Institute of Ophthalmology,  
Pondicherry, 605007 India

### Abstract

**Introduction:** Tamoxifen citrate is an anti-estrogen agent used in the treatment of breast carcinoma. Crystalline maculopathy is a rare complication of tamoxifen therapy. The clinical picture resembles that of idiopathic macular telangiectasia (IMT) Type 2, which is a more common clinical entity. **Objective:** To report a case of crystalline maculopathy secondary to tamoxifen and highlight the importance of the medical history and investigations in differentiating it from IMT Type 2. **Case:** A diabetic female with a past history of breast carcinoma treated with tamoxifen came to the hospital for a routine eye check-up. Crystalline deposits were seen in the parafoveal region in both the eyes. The spectral domain optical coherence tomography (SD-OCT) showed foveal cysts in the inner retinal layer and fundus autofluorescence (FAF) and fundus fluorescein angiography (FFA) were within normal limits. **Conclusion:** While tamoxifen maculopathy is reversible on stopping the therapy, IMT needs a long-term follow-up to monitor the potential risk of loss of vision due to choroidal neovascularization, hence necessitating the distinction between these two different clinical entities.

**Keywords:** Crystalline maculopathy, tamoxifen maculopathy, idiopathic macular telangiectasia Type 2.

### Case report

A 43-year-old lady, diagnosed with Type 2 Diabetes Mellitus two years ago, came to our hospital to be screened for diabetic retinopathy. Her best corrected visual acuity was 6/9 in both the eyes. The anterior segment examination was within normal limits. The fundus examination revealed a few refractile crystalline deposits in the parafoveal area with rest of the retina being normal in both the eyes (Figure-1). A clinical diagnosis of IMT Type 2 was made. For documentation, SD-OCT, FAF and FFA were

ordered. The SD-OCT showed foveal cysts in the inner retinal layers (Figure-2). The FAF showed normal macular hypofluorescence. The FFA was normal with no abnormality of parafoveal capillaries and no hyperfluorescence noted in the late phase (Figure-3), thus ruling out the diagnosis of IMT Type 2.

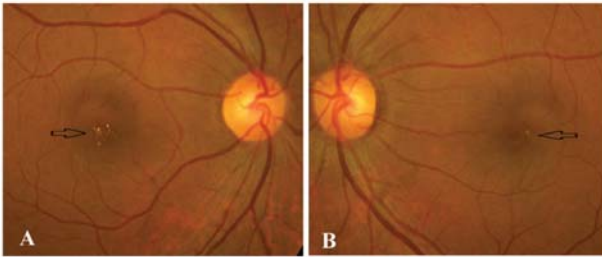
On reviewing her medical history, she revealed having undergone radiotherapy for breast carcinoma six years back. She had received tamoxifen citrate 20 mg/day for five years thereafter. At the time of examination, she had been off tamoxifen for the last year. Thus, the diagnosis of tamoxifen maculopathy was made.

Received on: 21.03.2014

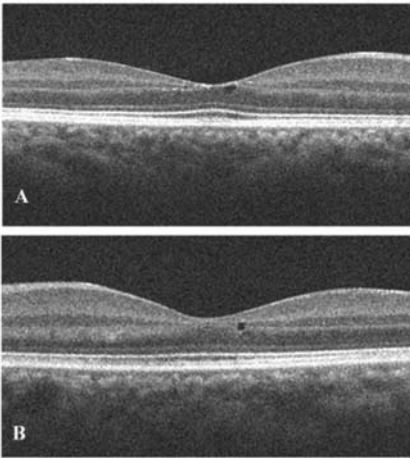
Accepted on: 02.06.2014

#### Address for correspondence

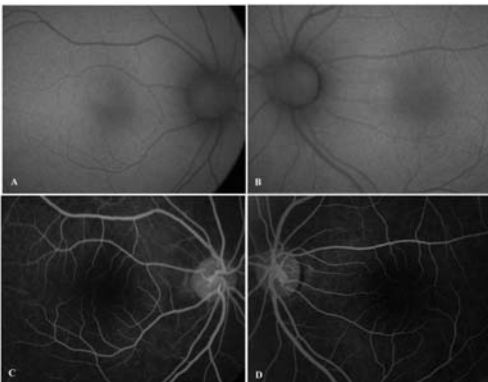
Dr Chinmay Nakhwa (M.S.), Consultant, Retina Services  
Aravind Eye Hospital & Postgraduate Institute of Ophthalmology,  
Pondicherry, 605007 India.



**Figure 1:** Colour fundus image of the right eye (Figure - 1A) and the left eye (Figure - 1.B) showing multiple refractile crystalline deposits in the macular area (black arrow)



**Figure 2:** Optical coherence tomography images of the right eye (Figure - 2 A) and the left eye (Figure - 2 B) showing inner retinal cysts. The outer retina and IS- OS junction is normal in both eyes.



**Figure 3:** Fundus autofluorescence and fluorescein images of the right eye (Figure - 3A and C) and the left eye (Figure - 3 B and D). The normal hypo autofluorescence and lack of diffuse leakage on angiography are distinguishing features from idiopathic macular telangiectasia (IMT).

## Discussion

Tamoxifen citrate is a selective estrogen receptor modulator and acts against breast cancer by occupying estrogen receptors. The incidence of ocular toxicity among patients receiving tamoxifen is 0.6%. Ocular toxicity includes vortex keratopathy, cataract, optic neuritis, refractile crystalline deposits in the retina and macular edema (Nayfield et al, 1996). The first case of tamoxifen retinopathy in patient taking a high doses of tamoxifen was described in 1978 (Kaiser-Kupfer et al, 1978). Though its dose has been reduced since then, retinopathy has also been described with a relatively low dose of 10-20 mg daily (Noureddin et al, 1999) and even in asymptomatic patients (Heier et al, 1994).

Tamoxifen retinopathy is a reversible disease; the visual function and macular edema improve after discontinuation of the drug, but the refractile deposits remain. These refractile deposits are located in the nerve fiber and inner plexiform layers, primarily in the perifoveal area, and are suggested to represent axonal degeneration. Optical coherence tomography (OCT) findings in a lower-dose tamoxifen therapy usually show a foveal cyst with disruption of the photoreceptor line, while a high-dose therapy can show cystoid macular edema (Park SS et al, 2009).

Similar refractile crystals are seen in patients with IMT Type 2. Degeneration and dysfunction of the foot plates of Muller cells form these crystalline deposits that are located in the nerve fiber layer and on OCT appear as cystic spaces in the inner retina. FAF has emerged as an important imaging tool in confirming the diagnosis of IMT Type 2. The loss of the physiologic hypoautofluorescence- that is increased autofluorescence in the fovea - is pathognomonic for IMT Type 2 (Wong T et al, 2009). FFA has been the gold standard for the diagnosis of IMT. The angiogram shows telangiectatic capillaries in the early phase with diffuse leakage in the late phase, predominantly

seen temporal to the fovea (Yannuzzi et al, 2006).

Tamoxifen retinopathy is a reversible disease on stoppage of the drug. Patients with IMT Type 2 have to be routinely examined as choroidal neovascular membrane formation is a known sight-threatening complication that needs prompt treatment.

### Conclusion

Tamoxifen-induced crystalline maculopathy is a rare complication. If intraretinal crystals are noted in these patients, FAF and FFA should be performed, primarily to rule out IMT Type 2, which can have similar-appearing lesions on the fundus examination as well as on the OCT.

### References

Gianni L, Panzini I, Li S, Gelber RD, Collins J, Holmberg SB, Crivellari D, Castiglione-Gertsch M, Goldhirsch A, Coates AS, Ravaioli A. (2006). Ocular toxicity during adjuvant chemoendocrine therapy for early breast cancer: Results from International Breast Cancer Study Group trials. *Cancer* 106: 505-13.

Heier JS, Dragoo RA, Enzenauer RW. (1994). Screening for ocular toxicity in asymptomatic patients treated with tamoxifen. *Am J Ophthalmol* 117: 772-75.

Kaiser-Kupfer MI, Kupfer C, Rodrigues MM. (1978) Tamoxifen retinopathy. *Cancer Treat Rep* 62: 315-20.

Nayfield SG, Gorin MB. (1996). Tamoxifen-associated eye disease: a review. *J ClinOncol* 14: 1018- 26.

Noureddin BN, Seoud M, Bashshur Z, Salem Z, Shamseddin A, Khali A. (1999). Ocular toxicity in low-dose tamoxifen: a prospective study. *Eye*. 13: 729-33.

Park SS, Zawadzki RJ, Truong SN, Stacey S, Choi SS, PhD, and Werner JS. (2009) Microcystoid maculopathy associated with tamoxifen use diagnosed by high-resolution fourier-domain optical coherence tomography. *Retina Cases Brief Rep* 3: 33-35.

Wong WT, Forooghian F, Majumdar Z, Bonner RF, Cunningham D, Chew EY. (2009). Fundus autofluorescence in type 2 idiopathic macular telangiectasia: correlation with optical coherence tomography and microperimetry. *Am J Ophthalmol*. 148(4):573-83.

Yannuzzi LA, Bardal AMC, Freund B, Chen K, Eandi CM, Blodi B (2006). Idiopathic macular telangiectasia. *Arch Ophthalmol* 124: 450-60.

Source of support: nil. Conflict of interest: none