

■ **Original article**

Pterygia measurements are more accurate with anterior segment optical coherence tomography – A pilot study

Welch MN¹; Reilly CD²; Kalwerisky K²; Johnson A¹; Waller SG²

¹Brooke Army Medical Center, Department of Ophthalmology, San Antonio, TX

²Wilford Hall Medical Center, Department of Ophthalmology, San Antonio, TX

Abstract

Introduction: Slit-lamp beam measurements of a pterygium can be difficult to reproduce accurately. Purpose: To compare standard slit-lamp beam measurements of pterygia to computer caliper measurements of Anterior Segment Optical Coherence Tomography (OCT) images.

Subjects and methods: Thirteen pterygia of ten patients were evaluated. Two physicians independently measured each pterygium using the slit lamp beam. Caliper measurements of two different OCT images of each pterygium were obtained. All measurements determined the distance from the limbus to the pterygium apex.

Results: The difference in the slit lamp beam measurements of each pterygium was calculated and the mean of the differences was 0.3 and the standard deviation was 0.32. The difference in the two OCT measurements of each pterygium was also calculated and the mean of the differences was 0.1 and the standard deviation was 0.12. A two-tailed t-test demonstrated a statistically significant difference in these measurements ($p = 0.0256$).
Conclusion: Anterior Segment Optical Coherence Tomography (OCT) gives significantly more reproducible results than the slit lamp beam for measurements of the distance of a pterygium's apex from the limbus. This tool may provide more accurate clinical assessment of extension of pterygia onto the cornea and may be useful for research purposes.

Key words: pterygium; pterygia; anterior segment optical coherence tomography; OCT

Introduction

A background search of the literature was done on Medline in July, 2010, to review previous research on measuring lesions of the anterior segment. Several studies demonstrate that anterior segment OCT is useful in making accurate measurements of the anterior segment. The focus of these studies have been: dimensions of the anterior segment such as depth and width of the anterior chamber angle (Baikoff et al 2004 and Goldsmith et al 2005), evaluation of the position of intraocular lenses, corneal thickness (Emmy et al 2007), scleral thickness

changes after the use of mitomycin C (Solomon et al 2004), and evaluation of various anterior segment lesions (Buchwald et al 2003 and Dada et al 2007).

To our knowledge, no studies have been done to specifically evaluate pterygia measurements using computerized caliper measurements (Adamis et al 1990 and Fujimoto et al 2002). A review was also performed to determine if literature exists to support that accurate measurement of extension of pterygia onto the cornea is, in fact, useful (Lin et al 1998 and Payman et al 2008).

Subjects and methods

Ten patients and thirteen nasal pterygia were enrolled. This study was approved by the Institutional Review Board and all participants gave their understanding and consent. Patients with significant ocular surface disease were excluded. The distance in

Received on: 6.09.2010 Accepted on: 12.11.2010

Address for correspondence

Mark N Welch, Brooke Army Medical Center,
Department of Ophthalmology, San Antonio,
TX

Email: mark.n.welch@gmail.com

Phone: 001-706-787-7155 Fax: 001-706-787-2666

millimeters from the limbus to the apex of the lesion on the cornea was taken by two ophthalmology physicians with the slit-lamp beam (BQ 900, Haag-Streit). A standard magnification of 16 was used and the variable aperture was focused on the pterygium from the limbus to the apex. Reading the size on the slit-lamp scale, measurements were taken from the limbus to the apex of the lesion on the cornea and recorded to the nearest tenth of a millimeter. Each pterygium was independently measured by each physician and recorded.

Next, two images were recorded of each lesion using OCT (Visante™ OCT – Optimized Anterior Segment Imaging and Biometry, Zeiss) imaging. Independent caliper measurements were made of the two OCT images of the pterygium. The OCT measurements were taken from the limbus to the apex of the lesion on the cornea and recorded to the nearest tenth of a millimeter.

The two slit-lamp beam measurements of the two different physicians were arranged in two columns and the difference between the two measurements was recorded in a third column. The mean difference was recorded by averaging the values in this third column. Then the standard deviation of these measurements was calculated. This same method was applied to the caliper measurements of two different OCT images of the same pterygia. A two-tailed t-test was applied to the mean difference column of slit-lamp measurements and the mean difference column of OCT image caliper measurements of the same pterygia, and a p-value was obtained.

Results

Figure 1 shows the difference of measurements in millimeters between the two slit-lamp beam measurements of each pterygium taken by two different physicians. The difference in the slit lamp beam measurements of each pterygium was calculated and the mean of the differences was 0.3 and the standard deviation was 0.32. Figure 2 shows the difference in measurements between two OCT images of each pterygium. The difference in the two OCT measurements of each pterygium was also calculated and the mean of the differences was 0.1 and the standard deviation was 0.12.

A p value of 0.0256 was obtained by applying a two-tailed t-test to the mean difference column of slit-

lamp measurements and the mean difference column of OCT image caliper measurements of the same pterygia. Figure 3 shows an OCT image of a pterygium and demonstrates the application of computerized calipers in measuring the distance from the limbus to the extent of the apex onto the cornea and also demonstrates measurement of the lesion’s thickness at the limbus.

Figure 1 – Difference in slit-lamp beam measurements of pterygia between physicians. Measurements were taken from the limbus to the apex of the lesion in millimeters.

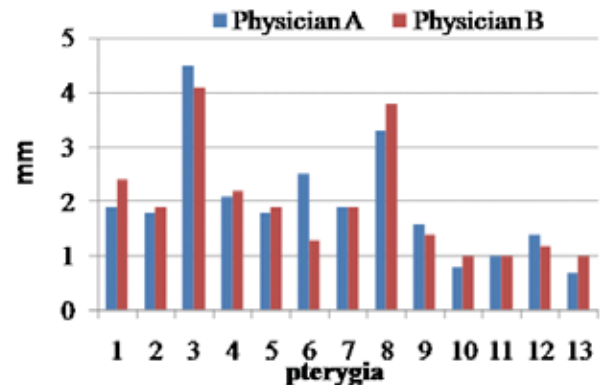


Figure 2 – Difference in caliper measurements of OCT images of pterygia between physicians. Measurements were taken from the limbus to the apex of the lesion in millimeters.

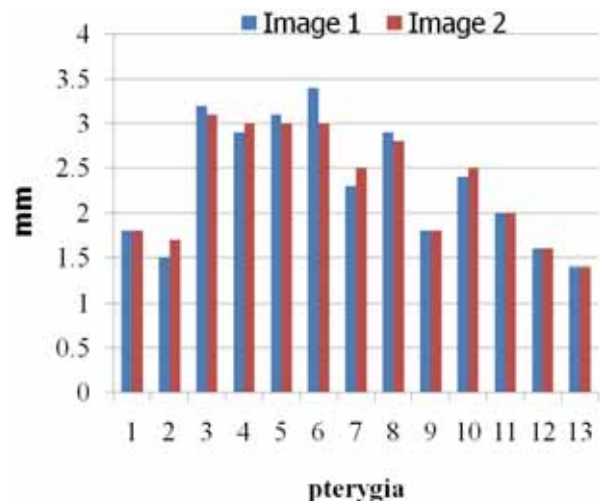
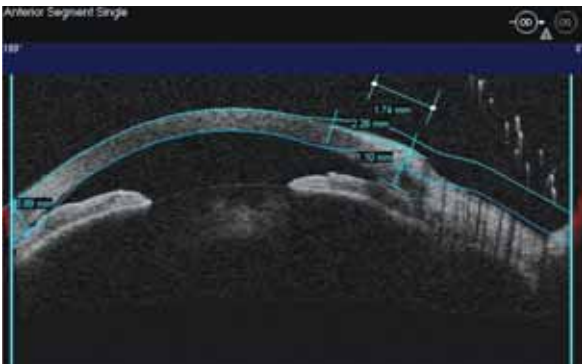


Figure 3 – OCT image of a pterygium with caliper measurements of a pterygium.



Discussion

A pterygium consists of interpalpebral, fibrovascular tissue which has a raised, whitish appearance and a conjunctival base with an apex that extends onto the cornea. Current methods for follow-up of pterygia include a yearly exam with slit-lamp measurement of the horizontal extent of the apex onto the cornea, photo documentation, manifest refraction and corneal topography. The criteria for surgical removal of pterygia include encroachment on the visual axis, vision changes including astigmatism, unacceptable cosmesis and intractable symptoms. Because of the common occurrence of these lesions, and, frequently, different physicians measuring the lesions with the slit-lamp beam on follow-up visits, there is “between observer” variability in these measurements. This study demonstrates a way to reduce that variability.

Two previous studies have shown that one of the strongest correlations of induced corneal astigmatism is related to the measured horizontal extent of the pterygium on the cornea measured from the limbus. Lin et al (1998) determined that > 2.2 millimeters caused significant astigmatism of > 2 Diopters and Payman et al (2008) demonstrated that an apex within 3.2 mm of the visual axis caused significant astigmatism.

This pilot study demonstrates that digital caliper measurements of OCT images of the horizontal extent of the apex of a pterygium onto the cornea is more accurate than the subjective measurements of the same lesion between physicians using a standardized method with the slit-lamp beam ($P=0.0256$). This indicates less “between observer” variability

when measuring pterygia by using a reproducible imaging approach that utilizes computerized caliper measurements such as the OCT. We have also shown in unpublished data that the same level of increased accuracy can be obtained with anterior segment high frequency ultrasound biomicroscopy (UBM) images using similar computerized caliper measurements.

Previous research done by Payman et al (2008) demonstrates that pterygium extension (distance from limbus to apex) and pterygium area (extension width) have a greater influence than width (measured at the limbus) on corneal astigmatism. This was determined by slit-lamp examination, refraction, and automated keratometry.

In light of Payman’s (2008) demonstration that pterygium extension and pterygium area had the most influence on corneal astigmatism, it is very interesting to note that in our current study, lesions more than 0.2 mm thick at the limbus were constantly irritating to patients and produced an intractable foreign body sensation and required surgical removal based on symptoms. The importance of this is yet to be determined. However, it should be noted that thickness measurements are only possible with OCT or UBM images and not with photographs. Since extension from the limbus onto the cornea (length), width (at the limbus), and thickness measurements can now be obtained, additional studies should be performed to study how the volume of lesions relates to patient symptoms and correlates to induced corneal astigmatism. This could be compared to previous studies, such as that by Payman (2008), which were only able to evaluate extension from limbus onto cornea (length), width (at the limbus) of these lesions. While currently unproven, this increase in accuracy may also be demonstrated for computerized caliper measurements of digital slit-lamp photos taken at a standard magnification. However, this method would not allow for thickness measurements.

Conclusions: Anterior Segment Optical Coherence Tomography (OCT) gives significantly more reproducible results than the slit-lamp beam for measurements of the distance of a pterygium’s apex from the limbus. This tool may provide more accurate clinical assessment of the extension of the pterygia onto the cornea and may be useful for research purposes. OCT can also be used to measure the thick-

ness of a pterygium. With this added measurement, future studies should be done to evaluate how the volume of the lesions affects symptoms, the resultant astigmatism and the need for surgery.

References

- Adamis AP, Starck T, Kenyon KR (1990). The Management of Pterygium. *Ophthalmol Clin North Am*; 2(4):611.
- Baikoff G, Lutun E, Ferraz C et al (2004). Static and Dynamic Analysis of the Anterior Segment With Optical Coherence Tomography. *J Cataract Refract Surg*; 30(9):1843-50.
- Buchwald HJ, Muller A, Kampmeier J, Lang GK (2003). Optical Coherence Tomography versus Ultrasound Biomicroscopy of Conjunctival and Eyelid Lesions. *Klin Monatsbl Augenheilkd*; 220(12):822-9.
- Dada T, Sihota R, Gadia R, et al (2007). Comparison of Anterior Segment Optical Coherence Tomography and Ultrasound Biomicroscopy for Assessment of the Anterior Segment. *J Cataract Refract Surg*; 33:837-840.
- Emmy YM, Mohamed S, Leung C et al (2007). Agreement Among 3 Methods to Measure Corneal Thickness: Ultrasound Pachymetry, Orbscan II, and Visante Anterior Segment Optical Coherence Tomography. *Ophthalmology*; 114(10):1842-1847.
- Fujimoto JG. Optical Coherence Tomography (2002). Introduction. In: Bouma BE, Tearney GJ, eds, *Handbook of Optical Coherence Tomography*. New York, NY, Marcel Dekker; 1-40.
- Goldsmith J, Li Y, Regina M et al (2005). Anterior Chamber Width Measurement by High-Speed Optical Coherence Tomography. *Ophthalmology*; 112(2):238-244.
- Lin A, Stern G (1998). Correlation between pterygium size and induced corneal astigmatism. *Cornea*; 17:28-30.
- Payman A, Mohammed-Salih, Ahmad F, Sharif (2008). Analysis of Pterygium Size and Induced Corneal Astigmatism. *Cornea*; 27:434-438.
- Solomon A, Kaiserman I, Raiskup F et al (2004). Long-term Effects of Mitomycin C in Pterygium Surgery on Scleral Thickness and the Conjunctival Epithelium. *Ophthalmology*; 111(8):1522-1527.

Source of support: nil. Conflict of interest: none