

■ **Original article**

A profile of eye-lid conditions requiring reconstruction among the patients attending an oculoplasty clinic in mid-western region of Nepal

Gautam P¹, Adhikari RK², Sharma BR³

¹Ophthalmologist, ²Professor and Oculoplastic Surgeon, ³Associate Professor and Oculoplastic Surgeon
Lumbini Eye Institute, Bhairahawa, Nepal

Abstract

Introduction: Some eyelid defects require reconstruction.

Objective: To study the eyelid conditions requiring reconstruction among the patients attending an oculoplasty clinic of a tertiary level eye institute.

Materials and methods: All the cases of eyelid reconstruction surgery of two years were retrospectively included in this study. The parameters studied were causes of eyelid defects, age and gender of the patients and the reconstructive surgical procedures.

Results: Of 43 cases that required eyelid reconstructive surgery 17 (39.53 %) had ocular tumors and 16 (37.2%) had trauma. The mean age of presentation was 42 years \pm 13.89 (4-84 years). Of the eyelid tumors, benign lesions were found in 7 (41.1%) followed by basal cell carcinoma in 5 (29%). The surgical procedures carried out were direct closure of defects in 15 (35%), excision of cicatrized tissue with skin graft in 7 (16%), reconstruction with rotational flap in 6 (14%), blepharoplasty in 4 (9%), gold weight in 4 (9%), lid sharing procedure (Cutler-Beard procedure) in 3(7%), lateral tarsorrhaphy in 2 (5%) and canalicular repair with silastic tube intubation in 2 (5%).

Conclusion: Ocular tumors are the most frequent conditions requiring eyelid reconstructive surgery. The common reconstructive procedures are direct closure followed by excision of cicatrized tissue with skin graft.

Keywords: eyelid, Oculoplastic surgeries, trauma, tumor

Introduction

Most eyelid disorders are not vision-threatening or life-threatening; however, many cause annoying symptoms such as burning, foreign-body sensation or pain (Carter SR, 1998). There are few population based studies on lid diseases especially in developing countries. Even less epidemiologic information exists for tumors from defined anatomic regions such as the eyelids. Congenital conditions, eyelid tumors and trauma are frequently encountered in hospital practice (Abidi UN et al 1996). A national population based survey of blindness in Nepal (1981) found a blindness prevalence rate of 0.84%, with trauma responsible

for 7.9% of monocular blindness (Brilliant GF et al 1988). However it didn't address morbidity due to lid pathologies.

Materials and methods

This was a retrospective hospital based study. Lumbini Eye Institute (LEI) is a tertiary level eye care hospital located in Siddharthanagar, Bhairahawa in Mid-western terai of Nepal. It has different ocular subspecialties available including oculoplastic services. A total of 127,987 patients were evaluated in LEI in the year 2007 and 148,573 patients in 2008, of which 5370 in 2007 and 6179 in 2008 had attended the oculoplastic clinic. Of the oculoplastic attendance 1129 and 2107 required surgical care in 2007 and 2008 respectively.

The present series of included all consecutives patients who reported to the Oculoplastic OPD, IPD

Received on: 18.06.2010 Accepted on: 10.11.2010
Address for correspondence
Dr Pragati Gautam, Ophthalmologist, Lumbini Eye Institute,
Siddharthanagar-3, Rupandehi, Nepal
Email: pragatigautam@hotmail.com
Contact Number: 00977-9841252921
Fax: 00977-71-520668

or emergency requiring surgical interventions. We reviewed their case files. The inclusion criteria were lid conditions that required reconstruction either congenital or acquired, trauma of lid involving lid margin/ canaliculi, cicatricial entropion, lagophthalmos. The lid conditions like blepharoptosis both congenital and acquired other than bhepharophimosis syndrome, entropion, ectropion other than cicatricial and primary acquired nasolacrimal duct surgery were excluded.

This study was carried out for the period of 2 years beginning from Jan 2007 to Dec 2008. Each case was diagnosed with standard methods and wherever needed diagnosis was confirmed by histopathological examination.

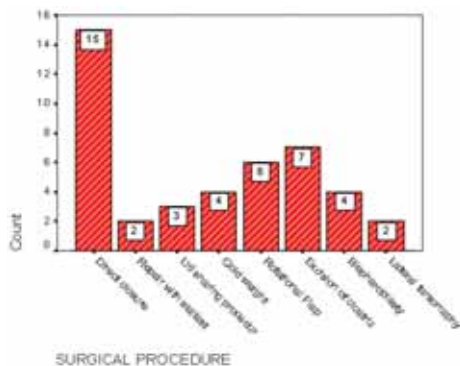
Statistics

Collected data were analyzed using SPSS 11.5 software.

Results

In our case series we encountered 43 cases out of which 17 (40%) were ocular tumors and 26 (60%) were other conditions. Other conditions included trauma 16(62%), lagophthalmos due to Bell's palsy 6 (23%) and congenital conditions 4 (15%) like coloboma eyelid, telecanthus, blepharophimosis.

Mean age of presentation of the disease was 42 ± 13.89 years. Male were 20 (46.5%) and female were 23(53.5%). Mean age of presentation of ocular trauma was 52 years. Mean age of presentation of ocular malignancy was 52 years. Eight (47%) of the patients having lid tumors were male and 9 (53%) were female. Out of lid tumors benign lesions were 7 (41%) (which included dermoid cyst, surface papillomatous naevus, sebaceous cyst), basal cell carcinoma were 5 (29%), sebaceous carcinoma 1(6%), squamous cell carcinoma 2 (12%) and congenital conditions (dermoid) were 2 (12%).



Out of the 43 cases, surgical procedures opted as per the cases were-direct closure 15 (35%), excision of cicatrized tissue with graft 7 (16%), reconstruction with rotational flap 6 (14%), blepharoplasty 4 (9%), gold weight 4 (9%), lid sharing procedure (cutler beard procedure) 3(7%), lateral tarsorrhaphy 2 (5%) and canalicular repair with silastic tube intubation 2 (5%).

Discussion

In this hospital based study tumor (40%) and trauma (37%) were the most common conditions requiring oculoplastic surgeries. Congenital condition requiring the oculoplastic care was 14%. In this study benign tumor was the commonest ocular lid tumor followed by basal cell carcinoma and squamous cell carcinoma. The mean age of presentation of ocular tumor was 52 years in our study. In a study done by Kumar et al (2008), out of the 277 ocular cases sent for histopathological examination from LEI, 59 were malignant. Squamous cell carcinoma was the most common (66.10%), followed by basal cell carcinoma (10.16%). In a similar study by Thakur et al (2005) basal cell carcinoma was reported as the commonest eyelid malignancy in eastern part of Nepal. Similarly, in a study done by Takamura & Yamashita (2005) among the total of 38 cases, 15 cases (39.5%) were diagnosed as basal cell carcinoma, 11 cases (28.9%) as sebaceous gland carcinoma, and 4 cases (10.5%) as squamous cell carcinoma. In addition, three cases were malignant melanoma, two adenocarcinoma, one Merkel cell carcinoma, one malignant peripheral nerve sheath tumor, and one malignant lymphoma. The mean age of presentation was 72.0 years (Takamura & Yamashita, 2005). In western countries, basal cell carcinoma (BCC) is the most common among malignant eyelid tumors, whereas, in Japan and other parts of Asia, the frequency of sebaceous gland carcinoma (SGC) and squamous cell carcinoma (SCC) is relatively high (Donaldson MJ et al 2002).

Ocular injury is a common problem of global concern (Barrillo et al 2000). WHO PBL survey (1981) had shown that 0.9% of population had signs or history of ocular trauma in Nepal. Adhikari RK et al (1994) in Rapti eye hospital had shown prevalence of ocular trauma 2.2 % to 4.9 % in 8 years (1986-93) study period. A study done by Karki et al (2008) had shown prevalence of ocular trauma in Nepal Eye Hospital,

Kathmandu as 1.6%. Their findings showed that out of 530 enrolled cases those with eyelid involvement were 30.

Trauma to eyelid was the second commonest condition needing oculoplastic care in our study. Most of the cases were due to trauma at home followed by a fall from a height, domestic activities, domestic violence, or agricultural field or trauma at work. This is in par with other studies done in Nepal including Nepal Blindness Survey. Lid trauma is a preventable form of the lid disorder and there is a need to educate rural population regarding preventive aspect and primary care. A larger population based studies is needed to validate the results of this study.

Conclusion

The eye-lid tumors and trauma are the most common conditions requiring oculoplastic surgeries. Among the eyelid tumors, benign conditions are the commonest followed by basal cell carcinoma.

References

Abidi UN, Tyagi V, Maheshwari V, Gogi R, Tyagi SP (1996) . Tumors of eyelid: a clinicopathologic study. J Indian Med Association; 94:405-9,416,418

Adhikari RK et al (1994). Ocular trauma in Rapti Eye Hospital Dang in 1993. J Nep Med Assoc; 112: 9-16.

Barrillo L, Mieler WF, Vinger PR (2000). Epidemiology and prevention of ocular trauma. Albert and Jakobiec. In: Principles and Practice of ophthalmology 2nd edition, WB Saunders Company; page 5262

Brilliant GF,Grasset NC, Brilliant JB (1988). The epidemiology of blindness in Nepal: report of the 1981 Nepal Blindness Survey; causes of blindness. The Seva foundation, Chelesa, MI.

Carter SR (1998). Eyelid Disorders: Diagnosis and Management. American Family Physician. 57 (11): 2695-2707.

Donaldson MJ, Sullivan TJ, Whitehead KJ, Williamson RM (2002). Eyelid basal cell carcinoma: non-Mohs excision, repair, and outcome. Br J Ophthalmol; 86(10): 1161–1165

Karki DB et al (2008). Ocular morbidity due to trauma. PMJN ; Vol. 8 (1): 1-11

Kumar R, Adhikari RK, Sharma M, DR Pokhrel DR, Gautam N (2008). Prevalence of ocular malignant tumors in western Nepal. Internet Journal of Ophthalmology and Visual Science; 7(2): 25.

Takamura H, Yamashita H (2005). Clinicopathological Analysis of Malignant Eyelid Tumor Cases at Yamagata University Hospital: Statistical Comparison of Tumor Incidence in Japan and in other countries. Jpn J Ophthalmol; 49:349–354.

Thakur SKDT, Sah SP, Lakhey M, Badhu B (2003). Primary malignant tumours of eye and adnexa in Eastern Nepal. Clin experiment ophthalmol; 31 (5):415-7.

Source of support: nil. Conflict of interest: none