

Case Report ● ● ● ●

Wound infection after cataract surgery: a report of two cases

Singh S K, Bharali P, Winter I
Biratnagar Eye Hospital, Biratnagar, Nepal

Abstract

Background: This is a report of 2 cases of fungal wound infection after cataract surgery (phacoemulsification). Both patients were noticed to have the fungal wound infection at the one-month follow-up after the surgery.

Observations: Although both patients had been advised to taper steroid containing antibiotic eye drops, they failed to do so. Despite intensive treatment with antifungal eye drops and oral antifungal agents, visual outcome was poor.

Conclusion: Fungal infection of the wound may occur in cataract patients in the post-operative period. This infection is probably more common in patients who have had a temporal incision and who are from an agricultural background living in a hot and humid climate.

Keywords: phacoemulsification, small incision cataract surgery, fungal infection

Introduction

Phacoemulsification with foldable intraocular lens is the standard technique for cataract surgery in developed countries. In developing countries, however, various forms of manual small-incision cataract surgery (SICS) are practised. In Nepal, SICS is a popular technique among ophthalmologists as it can be performed faster and yields a good surgical outcome (Hennig et al., 2003). Sclerocorneal wound infection after SICS as well as phacoemulsification is a rare complication. Frequent instillation of 10 % povidone iodine solution preoperatively, improved sterilization methods, aseptic no-touch technique during the intra-operative period, intracameral injection of Cefuroxime (Lundstrom et al, 2007) and; postoperatively, an effective combination of steroid containing antibiotic eye drops has reduced the incidence of postoperative infection significantly. Few case reports of postoperative wound infection after sclerocorneal tunnel incision have been published (Garg et al, 2003, Jain et al, 2008, Ormerod et al, 1993). In our hospital where more than twenty thousand cataract

surgeries were done in last two years, only two cases presented with wound infection.

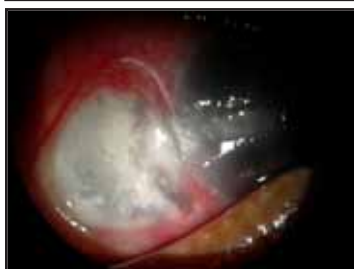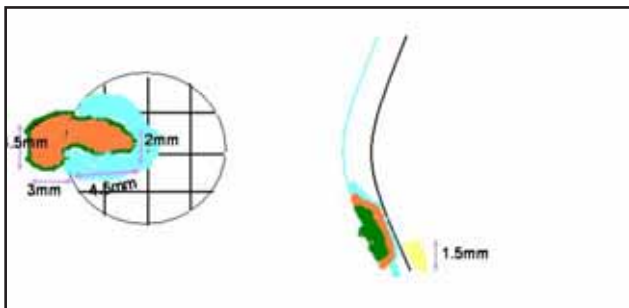
Case 1

A 60-year-old female underwent an uneventful phacoemulsification with implantation of a rigid posterior-chamber intraocular lens (5 mm) under local anaesthesia via the temporal sclerocorneal approach. On the first postoperative day, her visual acuity in the operated eye was 3/60. A mild central corneal edema with moderate anterior uveitis (cells 1 plus and flare 1 plus) was found. The patient was started on a combination of antibiotic and steroid containing eye drops (Ciprofloxacin and Dexamethasone), 10 times/day and Timolol 0.5 % eye drops two times/day. On the second postoperative day, the corneal edema had decreased and visual acuity improved to 6/24. The patient was discharged, prescribed with antibiotic and steroid containing eye drops to be used in a tapering dose and was asked to be reviewed after one month.

After six weeks she visited the hospital again with complaints of pain, redness, watering and diminished vision in the operated eye for the last two weeks. On examination, the visual acuity was 5/60 and ciliary congestion was present. A corneal epithelial defect of 2 mm x 4.5 mm with a full thickness corneal infiltrate was noticed on the temporal side of the cornea.

Received: 15.08.2009 Accepted: 12.12.2009
Correspondence and reprint request to: Dr Sanjay Kumar Singh, MD
Medical Director
Biratnagar Eye Hospital
Biratnagar, Nepal
Tel: 00977-21-533661
E-mail: sanjay.singh@erec-p.org

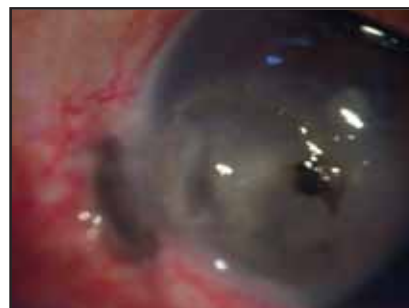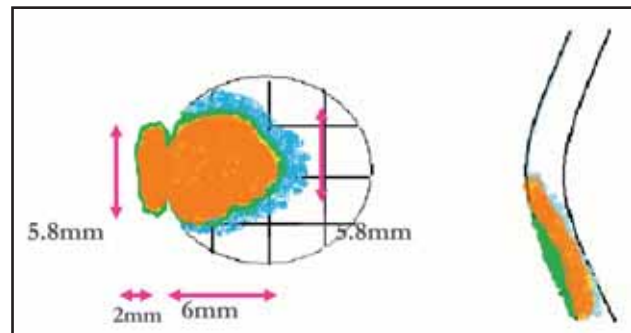
Additionally, an ulcerative lesion of about 3 mm x 4.5 mm in the adjacent sclera—and a 1.5 mm hypopyon were seen. Corneal scraping for Gram's stain and KOH wet mount was performed. Hyaline septate fungal filaments were seen. We started treatment with Natamycin eye drops half-hourly during the day time and 1 hourly at night, Atropine eye drops 3 times a day and Ketoconazole 200 mg twice daily orally for two weeks. After four days, the patient felt symptomatic relief and signs of healing were present after one week of the treatment. The patient was then discharged on Natamycin eye drops 1 hourly during the day time and 2 hourly at night and Atropine eye drops 3 times daily. After one month of treatment, the sclerocorneal ulcer had healed completely, leaving the patient with a visual acuity of hand movement in the affected eye. The sclerocorneal thinning persisted. The patient was kept on Natamycin eye drops 4 hourly and was asked to be reviewed after one month. At her last follow-up, the patient had no significant complaints but her right affected eye had become phthisical.



Sclero-corneal ulcer

However, at the time of the repeat visit to the hospital after 6 weeks, he said that he had not tapered the steroid containing antibiotic and had been using the eye drops 6 times/day. On examination, presenting visual acuity in both eyes was 3/60. Ciliary congestion was present in the right eye. Corneal epithelial defect was 6 mm in diameter, circular and in continuity with the adjacent scleral lesion. Underlying stromal infiltrate was present in the cornea. The necrotic ulcerative scleral lesion measured 2 mm x 6 mm. The sclerocorneal lesion was covered with black-coloured pigment. The patient's left eye was aphakic with no other associated pathology.

Scraping of the lesion was done for Gram's stain and KOH mount. It revealed hyaline septate fungal filaments. The same treatment as in Case 1 was commenced. The patient's complaints improved after one week. He was continued on Natamycin and Atropine eye drop and was reviewed at the corneal ulcer department one month later. By then his right eye vision was perception of light and the eye ball felt digitally soft. A sclerocorneal scar was present. The B scan examination revealed a peripheral 360 degree bullous choroidal detachment.



Corneal stromal infiltration and necrotic scleral lesion covered with black pigment

Case 2

A 65-year-old male farmer presented with a one-month-duration history of pain, redness and diminished vision in his right eye. He had undergone manual Small Incision Cataract Surgery (SICS) with implantation of a posterior-chamber intraocular lens (PCIOL) with the temporal approach in the same eye one-and-a-half months ago. At the time of discharge after the surgery he had had 6/18 vision and was prescribed steroid containing antibiotic eye drops in tapering dosage.

Surgical procedures

In our high-volume surgical setting, two operating tables are used by a single surgeon. While the surgeon operates on one patient, a theatre assistant cleans the periorbital area, drapes the eye, prepares the conjunctival flap and cauterizes bleeding vessels by thermal cautery of the next patient.

A standard phacoemulsification using phaco chop technique was performed. The rigid IOL was implanted after enlarging the incision to 5 mm. The SICS was performed using the "fish hook technique" wherein the tunnel has to be enlarged up to 6 mm for IOL insertion.

All intraoperative steps were performed by the surgeon from the temporal side. Intracameral injection of Cefuroxime was given at the end of surgery. The conjunctiva was placed back by cauterizing the ends with thermal cautery in both cases. Finally a subconjunctival injection of Gentamicin and Dexamethasone was given.

Discussion

In a high-volume surgical set up, most of Nepal's ophthalmic surgeons operate alternating between two tables, and the superior incision approach is the preferred entry site during cataract surgery. This allows the surgeon to operate by sitting at the head end of the patient and therefore eliminates the need to change his position while operating on either eye. As the superior incision site is covered by the upper eye lid, exposure time of the bare wound to the external atmosphere is decreased. This plays a protective role against wound and intraocular infection. Although the temporal incision site provides an easier surgical approach and decreases against-the-rule astigmatism (Barequet et al, 2004, Gokhale and Sawhney, 2005, Liu and Li, 1998), it is associated with a higher rate of intraocular infections (Lundstrom et al., 2007). In 182 tunnel incisions (phacoemulsification and manual SICS) from the temporal approach in a two-months period (1 May 2007 to 29 June 2007), we observed two cases of fungal sclerokeratitis. In both cases, the scleral incision was covered by the conjunctiva by the application of thermal cautery at the limbal site. An unpublished study done at Sagarmatha Chaudhary Eye Hospital showed that conjunctival ends are not firmly attached in nearly five percent of all cases on the first postoperative day keeping the scleral tunnel incision exposed (personal communication).

Several epidemiological studies have estimated the prevalence of fungal keratitis ranging from 25 % to more than 50 % percent in tropical countries (Srinivasan et al., 1997, Leck et al., 2002, Boonpasart et al., 2002). A hot and humid climate and an involvement in agricultural activities that can lead to trauma with vegetative matters could be the major factors for the high prevalence of fungal corneal ulceration (Srinivasan et al, 1997, Leck et al, 2002, Laspina et al, 2004). An agricultural environment and a prolonged wound exposure time because of the temporal incision along with a poorly-covered scleral incision created a favourable atmosphere for fungal hyphae inoculation into the wound site.

Infectious sclerokeratitis of fungal origin is an uncommon condition after SICS and phacoemulsification. Risk factors associated with infectious scleritis are diabetes mellitus, prior scleritis, previous surgery, trauma and irradiation after pterygium surgery, use of topical steroids, antimetabolite use and systemic infections (Chung et al, 2007). Both of our patients had good visual outcome at the time of discharge and were discharged with a combination eye drops of antibiotic and steroid on a tapering dosage. One patient did not taper the dose of the steroid. The other had tapered the dose of the combination eye drops but still continued the eye drops at the time of presentation to the hospital. Both patients had severe fungal sclerokeratitis with late presentation. The steroids reduced the inflammation but at the same time lead to immunologically-compromised surroundings. This created a suitable environment for fungal growth without increasing the symptoms in both the patients.

In sclerocorneal phacoemulsification and Small Incision Cataract Surgery, through a lamellar dissection a sclerocorneal tunnel is created and the anterior chamber is entered through the cornea. Usually, about 15 square millimetres of a bare scleral flap area is created during phacoemulsification for the implantation of a rigid 5 millimetre posterior-chamber lens, whereas nearly 25-30 square millimetres of a bare scleral flap area is created in small incision cataract surgeries. After completion of the surgery, the internal flap gets attached with the external flap by formation of the anterior chamber with Ringer Lactate solution. Ormerold hypothesized of a potential space between the internal and external flaps and that such a space can lead to

the formation of an abscess cavity in the event of an infection (Ormerod et al, 1993). Improper wound design and damaged wound flap increase the risk of infection. In Case 1, the scleral necrosis size was larger than the extent of the corneal ulcer. Probably the sclera was the initial infection site followed by an extension into the cornea. In Case 2, the corneal lesion was larger than the scleral incision. In this case, the keratitis probably could be the initial lesion with a later extension into the sclera.

The source of microorganism remained unclear. The eyelids, lacrimal sac and the conjunctival cul de sac are the possible source of microorganisms for endophthalmitis. None of these factors could be identified in these two patients. Unlike in other reported series, diabetes mellitus was not diagnosed in both patients (Chung et al, 2007; Maskin, 1993). Both patients had not been under treatment with systemic immunosuppressive drugs.

Management of sclerocorneal wound infection in a postoperative patient is a therapeutic challenge because of the diffuse nature of infection and involvement of the limbus (Jhanji et al, 2007, Garg et al, 2003, Jain et al, 2008). Most of the available antifungal agents are fungi static (Garg et al, 2003). Early detection of the infectious organism and aggressive treatment are necessary. Available treatment options are topical instillation of antifungal eye drops, intracameral injection, oral antifungal agents, surgical debridement of infected site to decrease the load of the fungal hyphae and lamellar keratoplasty. Prognosis for visual recovery remains poor despite aggressive treatment (Garg et al., 2003, Jain et al., 2008). Both patients in this series had deep fungal keratitis and received surgical debridement, intensive topical and systemic antifungal therapy. Both patients had poor anatomical and visual outcome in spite of an intensive treatment scheme.

Conclusion

Cataract surgery with the temporal approach has advantages like neutralizing the astigmatism and offering a more comfortable position for the surgeon. But the risk of wound infection due to the longer exposure time of the wound during blinking remains a noticeable disadvantage. Fungal sclerokeratitis is a specific risk in patients from an agricultural background

with a temporal incision and prolonged use of steroid eye drops. Visual and anatomical outcome remains poor in these patients despite aggressive management with topical and systemic antifungal medications.

References

- Barequet I S, Yu E, Vitale S, Cassard S, Azar D T, Stark W J (2004). Astigmatism outcomes of horizontal temporal versus nasal clear corneal incision cataract surgery. *J Cataract Refract Surg*; 30: 418-23.
- Boonpasart S, Kasetsuwan N, Puangsricharern V, Pariyakanok L, Jitpoonkusol T (2002). Infectious keratitis at King Chulalongkorn memorial hospital: a 12-year retrospective study of 391 cases. *J Med Assoc Thai*; 85: S217-30.
- Chung P C, Lin H C, Hwang Y S, Tsai Y J, Ngan K W, Huang S C, Hsiao C H (2007). *Paecilomyces lilacinus* scleritis with secondary keratitis. *Cornea*; 26: 232-4.
- Garg P, Mahesh S, Bansal A K, Gopinathan U, Rao G N (2003). Fungal infection of sutureless self-sealing incision for cataract surgery. *Ophthalmology*; 110: 2173-7.
- Gokhale N S, Sawhney S (2005). Reduction in astigmatism in manual small incision cataract surgery through change of incision site. *Indian J Ophthalmol*; 53: 201-3.
- Hennig A, Kumar J, Yorston D, Foster A (2003). Sutureless cataract surgery with nucleus extraction: outcome of a prospective study in Nepal. *Br J Ophthalmol*; 87: 266-70.
- Jain V, Garg P, Sharma S, Vemuganti G K (2008). Sutureless wound infection by unusual acid-fast organisms. *Cornea*; 27: 615-8.
- Jhanji V, Sharma N, Mannan R, Titiyal J S, Vajpayee R B (2007). Management of tunnel fungal infection with voriconazole. *J Cataract Refract Surg*; 33: 915-7.
- Laspina F, Samudio M, Cibils D, Ta, C N, Farina N, Sanabria R, Klauss V, Mino De Kaspar H (2004). Epidemiological characteristics of microbiological results on patients with infectious corneal ulcers: a



- 13-year survey in Paraguay. *Graefes Arch Clin Exp Ophthalmol*; 242: 204-9.
- Leck A K, Thomas P A, Hagan M, Kaliamurthy J, Ackuaku E, John M, Newman M J, Codjoe F S, Opintan J A, Kalavathy C M, Essuman V, Jesudasan C A, Johnson G J (2002). Aetiology of suppurative corneal ulcers in Ghana and South India, and epidemiology of fungal keratitis. *Br J Ophthalmol*; 86: 1211-5.
- Liu Y, Li S (1998). Phacoemulsification and foldable lens implantation through a temporal clear corneal tunnel incision. *Zhonghua Yan Ke Za Zhi*; 34: 428-30.
- Lundstrom M, Wejde G, Stenevi U, Thorburn W, Montan P (2007). Endophthalmitis after cataract surgery: a nationwide prospective study evaluating incidence in relation to incision type and location. *Ophthalmology*; 114: 866-70.
- Maskin S L (1993). Infectious scleritis after a diabetic foot ulcer. *Am J Ophthalmol*; 115: 254-5.
- Ormerod L D, Puklin J E, Mchenry J G, Mcdermott M L (1993). Scleral flap necrosis and infectious endophthalmitis after cataract surgery with a scleral tunnel incision. *Ophthalmology*; 100:159-63.
- Srinivasan M, Gonzales C A, George C, Cevallos V, Mascarenhas J M, Asokan B, Wilkins J, Smolin G, Whitcher J P (1997). Epidemiology and aetiological diagnosis of corneal ulceration in Madurai, South India. *Br J Ophthalmol*; 81: 965-71.

Source of support: nil. Conflict of interest: none