

Original article

Amniotic membrane transplantation: Current indications in a tertiary eye hospital of eastern Nepal

Diwa Hamal¹, Sanjay Kumar Singh¹, Binaya Lamichhane¹, Archana Sharma²,
Afaque Anwar¹, Vijay Mahaseth¹
¹Biratnagar eye hospital
²Nepal eye hospital

Abstract

Introduction: Amniotic membrane has unique properties that can be helpful to treat different ocular surface diseases. **Objectives:** To report our experience with 100% glycerol preserved amniotic membrane at 4°C and fresh amniotic membrane transplantation (AMT) with and without limbal graft for ocular surface reconstruction. **Materials and methods:** Retrospective case study of 211 eyes of 211 patients was conducted at Biratnagar Eye Hospital from June 2008 to March 2014. The cases were evaluated in terms of demographic parameters, preoperative diagnosis and the type of surgery performed. **Results:** The most common indication for surgery was Pterygium (90 eyes, 42.65%), followed by symblepharon (57 eyes, 27.01%), chemical injury (35 eyes, 16.58%), socket reconstruction (9 eyes, 4.26%), shield ulcer (6 eyes, 2.84%), PED (4 eyes, 1.89%), Steven Jonson's syndrome (5 eyes, 2.36%), dry Eye (2 eyes, 0.94%), Corneal Degeneration (2 eyes, 0.94%), bullous keratopathy (1eye, 0.47%). The mean age was 28.12 ±17.2 years (age range 3-78 years). More men (161, 76.30%) underwent surgery than women (50 eyes, 23.69%). Symblepharon (24 eyes, 36.36%) was the major cause of surgery in pediatric group. The mean follow-up was 7 months (range 2-36, months). Resurgery was needed in (18 eyes, 8.53%) of which symblepharon (7eyes, 39%) was the major cause. AMT was done in 189 (89.57%) eyes and AMT with conjunctival limbal graft was done in 22(10.42 %) cases. Infectious, inflammatory, or allergic reactions were not encountered in any patient. **Conclusion:** All patient experienced increased ocular comfort with anatomical restoration of corneal and conjunctival surfaces. AMT alone or in combination with limbal graft aids in ocular surface reconstruction.

Keywords: AMT, Ocular surface reconstruction, symblepharon, pterygium, chemical

injury.

Introduction

Amniotic membrane is the inner most of the three layers forming the fetal membranes. It is a translucent membrane composed of an inner

layer of epithelial cells, planted on a basement membrane that in turn is connected to a thin connective tissue membrane by filamentous strands (Dua H.S et al, 2004). The amnion varies in thickness from 0.02 mm to 0.5 mm. It contains no blood vessels and has no direct blood supply. Bourne (1960) described amnion as consisting of five layers from within outward

Received: 04/02/16

Accepted: 21/06/16

Address for correspondence

Dr Diwa Hamal, MD Ophthalmology
Biratnagar eye hospital, Rani-17, Atithi marg, Biratnagar, Nepal.
Email: diwa222@hotmail.com

(a) epithelium (b) basement membrane (c) compact layer (d) fibroblast layer and (e) spongy layer.

In 1910, Davis first reported use of amniotic membrane in human medicine. In 1940, De Roth first reported the use of living amniotic membrane for the reconstruction of conjunctival defects due to burn. Sorsby et al (1946; 1947) reported the successful use of amniotic membrane as a patch graft in the treatment of acute ocular burns.

Maral et al, (1999) preserved human amniotic membrane in 85% glycerol solution at 4°C for over a year and showed that its performance was as good as fresh amnion in the treatment of partial thickness skin burns and reducing bacterial levels in infected burn wounds (in rats).

Amniotic membrane has been shown to act as a scaffold for cell growth, epithelial wound healing, anti-inflammatory, anti-angiogenic, anti-fibrotic, anti-microbial, pain reduction, and epithelialization effects. These mechanisms are attributed to a wide range of biological factors present in AM, epidermal growth factor, fibroblast growth factor, hepatocyte growth factor, and transforming growth factor b1 (Allen CL et al, 2013). Amniotic membrane also inhibits protease activity. Amniotic membrane, rather than providing a substrate, acts as a “bandage contact lens” allowing epithelialization to occur under its cover (Azuaara-Blanco A et al, 1999).

The effects of glycerol as preservative on the structural and biochemical integrity of cryopreserved AM are unclear. Following freezing AM is considered non-viable and following thawing soluble factors presumed to be beneficial are extensively depleted from the tissue, potentially reducing its efficacy (Allen CL et al, 2013). There are significantly lower levels of angiogenic factors in cryopreserved AM compared to fresh (Wolbank S et al, 2009).

This study examines the indications for AMT with and without conjunctival limbal autograft (CLAU), including demographics and surgical procedure. The findings of the study are compared with those in the published literature.

Materials and methods

The study was carried out at Biratnagar eye hospital. Patient records of all cases of AMT with or without limbal autograft between June 2008- March 2014 were retrospectively reviewed. Information collected from the records included: age, sex, preoperative diagnosis, preoperative visual acuity of both eyes, type of surgery (AMT with or without limbal autograft), the procedures performed in addition to the main surgery, and complications. Indications for AMT were divided into ten main diagnostic categories: Pterygium, Symblepharon, Chemical injury, Socket reconstruction, Shield ulcer, PED, Steven Johnson’s syndrome, Dry Eye, Corneal degeneration, Bullous keratopathy.

Surgical technique

Preparation and preservation of amniotic membrane

Placenta was collected after elective caesarean section from healthy woman. It was thoroughly cleaned with normal saline solution and transported to the eye hospital in normal saline with Gentamycin. Further cleaning was done at BEH. Amnion was separated from chorion then was washed with normal saline solution with gentamicin and amphotericin B. It was mounted on sterile whatman filter paper grade number 1 and was kept in normal saline solution with gentamicin and amphotericin B. The amniotic membrane was then stored in 100% glycerol and refrigerated to 4° centigrade. Investigations done included HIV, HbsAg, VDRL of the mother. The amnion was removed from the glycerol and kept in Normal saline for 30 min in room temperature before surgery. AMT was performed in the operating room under local anesthesia or general anesthesia.

During surgery according to the indications preliminary steps were done. Pterygium excision, symblepharon lysis was done, fornices were freed. Superficial keratectomy was done to remove abnormal corneal tissue. Chelation of lime particle with 1% EDTA disodium salt was done. For the cases with symblepharon, bare sclera and the cornea thus prepared was then covered with amniotic membrane with stromal side down. Fornix reconstruction was done. The amniotic membrane was sutured through the episcleral tissue to the edge of conjunctiva along the bare sclera border with interrupted 8-0 vicryl suture and to the cornea approximately 1 to 2 mm inside the limbus with circumferential interrupted 10-0 nylon suture. The number of sutures depended on the size of the defect and AMG used. Bandage contact lens was applied at the end of surgery.

Postoperative regimen

Frequent application of topical antibiotic-steroid combination dexamethasone and ciprofloxacin eye drops, with tapering over 6-8 weeks. Ointment antibiotic and steroid combination was advised to apply at night for 6-8 weeks. Artificial tear substitute was advised frequently to instill in the operated eye depending on the indication of surgery. In cases of chemical burn tetracycline ointment twice daily and vitamin C 500 mg were given thrice daily for two weeks.

Results

Demographics

The amniotic membrane transplantation was started in BEH in 2008. A total of 211 were reviewed for this study. There were 211, 161(76.30%) male and 50(23.69 %) female. Out of 211, 189 (89.57%) eyes underwent AMT and 22 (10.42%) eyes underwent AMT with CLAU for associated limbal stem cell deficiency.

The mean patient age at the time of surgery was 28.12 ± 17.2 years (range 3 to 78 years). Out of 211, 100 (47.39 %) were right eyes and 111(52.60 %) left. The maximum number of eyes, 48 (22.74%) was in the age group of 30-39 years.

Pre-operative visual acuity

In most of the eyes with severe chemical injury, preservation of globe was the main aim of the surgery. More than half of the cases i.e. 117(55.45%) had pre operative visual acuity of less than 3/60 at presentation.

Indications

The most common indication for surgery was pterygium 90 eyes (42.65%), followed by symblepharon 57 eyes (27.01%), chemical injury 35 eyes (16.58%), socket reconstruction 9 eyes (4.26%), shield ulcer 6 eyes (2.84%), PED 4 eyes (1.89%), Steven Johnson's syndrome 5 eyes (2.36%), dry eye 2 eyes (0.94%), corneal degeneration (2 eyes, 0.94%), and bullous keratopathy (1 eye, 0.47 %). Indications for AMT are mentioned in the Table 1.

There were 66(31.27%) pediatric eyes, including 45(68.18%) male and 21(31.81%) female. Most common indication for surgery in pediatric group was symblepharon i.e. 24 cases (36.36%), whereas pterygium was the major indication in adult group i.e. 70 cases (48.27%).

Demography of Pediatric Patient

More than two-thirds of the pediatric cases were male i.e. 68% and about same proportion had operation in left eyes (62%). More than 90% of the cases had gone for AMT and significant proportion of pediatric cases had gone for resurgery i.e. 16.7%. Resurgery in pediatric patient included recurrent symblepharon (5 eyes), SJS with recurrent corneal epithelial defect (3eyes), sloughing of AMG before the epithelial defect had healed in lime injury (1 eye), recurrence of fornix contracture after socket reconstruction (1 eye) and early disintegration of AMG in shield ulcer (1eye).

AMT with and without limbal autograft

The AMT alone was done in 189 (89.57%) eyes, (129 adult and 60 pediatric). AMT with limbal autograft was done in 22 (10.42%) eyes, (6 pediatric, 16 adult). The limbal autograft was done in eyes with limbal stem cell deficiency. These included 8 eyes with chemical injury (1 acid, 7 lime), 9 cases of pterygium, and 5 cases of symblepharon.

Epithelial healing

In most of the cases epithelial healing completed by the end of 6 weeks. Pain was relieved after AMT. All patients except 18 with complication reported increased ocular comfort postoperatively. The amniotic membrane was absorbed within 4-6 weeks with good ocular surface integrity.

Re-surgery

Re-surgery was needed in 7 adult and 11 pediatric eyes. These included recurrent multiple symblepharon 7 eyes (39%), SJS with recurrent corneal epithelial defect and conjunctival scarring 4 eyes (22%), recurrent pterygium 3 eyes (17%), sloughing of AMG before the epithelial defect had healed in lime injury 1 eye (5.5%), recurrence of fornix contracture after socket reconstruction 1 eye (5.5%), graft rejection in 1 dry eye (5.5%) and early disintegration of AMG in shield ulcer 1 eye (5.5%).

Follow up

On 2 months post surgery, all 211 patients came for follow up, but by the end of 8 months only 100 patients showed up. Our patient comprises of the entire referred patient from the Eastern Nepal as well as from the neighboring countries like India (Assam, Sikkim, Bihar) and Bangladesh. To follow all these patients regularly was a difficult task. Reasons for not coming for follow up were assumed to be the long travelling distance, cost for travelling to the hospital.

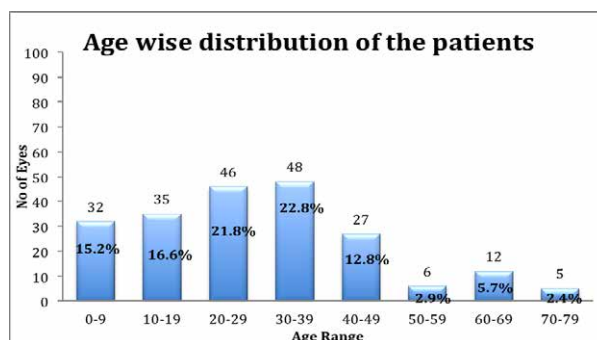


Figure 1: Age wise distribution of the patient who underwent surgery.

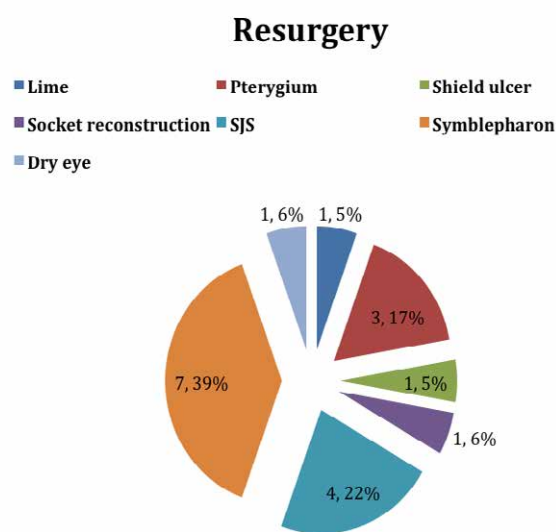


Figure 2: Indications that needed re-surgery.

Table 1: Indications for AMT and AMT with CLAU

Indications	Frequency (N=211)	AMT (189)	AMT+CLAU (22)
Chemical injury	35(16.58%)	27(77.14%)	8(22.85%)
Acid	13(6.16%)	12(92.30%)	1(7.69%)
Lime	22(10.42%)	15(68.18%)	7(31.81%)
Corneal Degeneration	2(0.94 %)	2(100%)	0
BK	1(0.47 %)	1(100%)	0
Dry Eye	2(0.94 %)	2(100%)	0
PED	4(1.89%)	4(100%)	0
Pterygium	90(42.65%)	81(90%)	9(10%)
Shield ulcer	6(2.84%)	6(100%)	0
Socket Reconstruction	9(4.26%)	9(100%)	0
SJS	5(2.36%)	5(100%)	0
Symblepharon	57(27.01%)	52(91.22%)	5(8.77%)

Table 2: Indications based on age

Indication (211)	0-9	10-19	20-29	30-39	40-49	50-59	60-69	70-79
Acid	0	2 (5.7%)	5 (10.8%)	4 (8.3%)	1 (3.7%)	1 (16.7%)	0	0
Lime	9 (28.2%)	3 (8.6%)	2 (4.4%)	4 (8.3%)	2 (7.4%)	0	2 (16.7%)	0
Corneal Degeneration	0	1(2.9%)	0	0	0	0	0	1(20%)
BK	0	0	0	0	0	0	1 (8.3%)	0
Dry Eye	0	0	0	2 (4.2%)	0	0	0	0
PED	0	0	1 (2.2%)	1 (2.1%)	1 (3.7%)	0	1 (8.3%)	0
Pterygium	12 (37.5%)	8 (22.8%)	15 (32.6%)	26 (54.1%)	15 (55.6%)	5 (83.3%)	6 (50%)	3 (60%)
Shield ulcer	0	2 (5.7%)	1 (2.2%)	1 (2.1%)	2 (7.4%)	0	0	0
Socket Reconstruction	0	3 (8.6%)	4 (8.7%)	2 (4.2%)	0	0	0	0
SJS	1 (3.1%)	2 (5.7%)	1 (2.2%)	1 (2.1%)	0	0	0	0
Syblepharon	10 (31.2%)	14 (40%)	17 (36.9%)	7 (14.6%)	6 (22.2%)	0	2 (16.7%)	1 (20%)
Total	32	35	46	48	27	6	12	5

Table 3: Demography of pediatric patients

Gender	Male	45(68.18%)
	Female	21(31.81%)
Laterality	RE	25(37.87%)
	LE	41(62.12%)
Management	AMT	60(90.90%)
	AMT +CLAU	6(9.09%)
Resurgery		11(16.66%)

Discussion

In this study, more males 161(76.30%) underwent AMT than females 50(23.69%). The observed trends in the developing countries are males frequently have more privileged access to health care and treatment facilities, as well as male being more exposed to outdoor activities thus may have made up more of the surgical population.

We have used both fresh as well as 100% glycerol preserved amnion preserved at 4°C. Glycerol can reduce intracellular virus infectivity but its effects are dependent on concentration, time and temperature (Marshall L et al, 1995).

Glycerolized tissue is nonviable, compared to the viable cryopreserved skin. The potential advantage of glycerol over cryopreservation may be the antibacterial effects of glycerol. The structures of the tissue and cells are maintained because intracellular water is removed without

altering the intracellular ionic composition. In a 9 years (1987-1995) study bacteriological data of 1929 cadaver skin preserved in glycerol showed that the antibacterial effect of glycerol is slow but effective. (Baare Vet al, 1998)

In a study done by Maral et al (1999) qualitative bacterial culture studies of the preserved amniotic membrane in 85% glycerol at 4°C demonstrated that there was no bacterial growth in any specimen after a period of more than a year. Following rehydration, glycerol-preserved membrane is soft, pliable and differed from fresh amnion only in its translucent appearance. There is no immunologic response because the cells of glycerol preserved amnion are nonviable and vascularization does not occur. The lack of vascular ingrowth prevents exposure to blood-borne antigen-presenting cells such as monocytes. It has been demonstrated that storage of HIV-1 infected cadaver skin in 85% glycerol at 4°C results in complete inactivation of the virus after 5 days. (Cameron PU et al, 2000)

Pre-operative visual acuity

In most of the eyes with sever chemical injury preservation of globe was the main aim of the surgery. 117 (55.45%) cases had pre operative visual acuity of less than 3/60 at presentation.



Late presentation of the cases was due to various causes worsening the disease process. Travelling for days to reach the hospital, financial issue and social negligence.

Indications

Pterygium

In our study all eyes were of grade 3 and 4 pterygium. The 81(90%) eyes had AMT done and 9 (10%) eyes had AMT with limbal autograft done. Resurgery was done with AMT and CLAU in 3 (3.33%) eyes with recurrence. In a study the recurrence rates of primary, recurrent, and all pterygia in conjunctival limbal autograft (group 1) were 3.6%, 16.7%, and 7.5% where as AMT (group 2) were 3.7%, 18.2%, and 7.9% respectively. In a study by Ma DH et al Three recurrences (3.8%) in AMT group, three recurrences (5.4%) in the CAG group, and two recurrences (3.7%) in the topical MMC group was observed (Ma D. H et al, 2000). The outcome of AMG in pterygium surgery is comparable to conjunctival limbal autograft. AM can serve as useful alternative to conjunctival grafts when there exists a very large conjunctival defect to cover in primary double-headed pterygium, in previous multiple failed surgeries or in the context of preserving superior bulbar conjunctiva for future glaucoma surgeries.

Symblepharon

The antiadhesive properties of the amniotic membrane were also explored in (57, 27.01%) eyes with symblepharon. The surgery achieved its goal by the release of symblepharon, closure of corneal epithelial defect, and reconstruction of conjunctival mucosal surface with prevention of adhesions. Only AMT was done in 52 (91.22%) eyes and AMT with limbalautograft was done in 5(8.77%) eyes. All patients reported increased ocular comfort post operatively. The patient's subjective assessment of se-verity of pain and discomfort was noted and scored as 1 (no discomfort), 2

(mild, minimal discomfort not interfering with daily activities), 3 (moderate, interfering with daily activities), or 4 (severe, unbearable).

The amniotic membrane absorbed within 4-6 weeks with good ocular surface integrity. Re-surgery with release of symblepharon and AMG was done in 7 (12.28%) eyes with recurrent symblepharon. There is inhibition and arrest in fibroblast proliferation following contact with amniotic membrane, it induces a down regulation of transforming growth factor, signaling responsible for fibroblastic activation in wound healing (Azura-Blanco A et al, 1999). As an anatomical barrier, keeps the potentially adhesive surfaces apart. Amniotic membrane has been also used to reconstruct conjunctival defects created during surgical removal of a large lesion or during symblepharon lysis (Tseng SCG et al, 1997).

Chemical burn

Meller et al (2000) performed AMT within two weeks after injury in 13 eyes and concluded that AMT is effective in promoting re-epithelialization and reducing inflammation in the acute stage of chemical injury, thereby preventing scarring sequelae in the late stages. In this series, AMT was done in 27(77.14%) eyes and AMT with limbalautograft was done in 8(22.85%) eyes. EDTA has been used in cases of lime injury to prevent the formation of slaked lime that produce considerable heat. Heat causes deep ischemic necrosis & strongly shrinking scars. Both the disodium and calcium derivatives of ethylene diamine tetraacetic acid (EDTA) inhibites lysis in concentrations as low as 10^{-4} M. (Itoi M et al, 1969). Hook et al (1971) believes that EDTA chelates the calcium necessary for collagenase activity. Guidelines for effective doses are not available, but 0.2 M solution has been used safely (Slansky H.H et al, 1971). We used 1% EDTA disodium salt in this study. That loosened the lime particles for easy removal in all cases. Patients were symptoms free after the surgery. Pain was relieved after

AMT. Epithelial healing completed by the end of 6 weeks. Resurgery was needed in 1 (4.54%) eye of lime injury where that had grade IV burn with limbus involvement and symblepharon formation. Hence, symblepharon release, AMT and limbalautograft was done.

Socket reformation

Amniotic membrane has been used as a cover for orbital prostheses and successfully used for the closure of a conjunctival defect following hydroxyapatite orbital implant exposure (Lee-Wing MW, 2003). Stewart et al (2002) successfully used AM for reconstruction of the upper lid and the fornix in cryptophthalmos.

In this series, AMT with socket reformation was done in 9 (4.26%) eyes. 1 (11.11%) eye-needed resurgery. AMT with conformer was put in all these eyes. It is well suited for eye socket reconstruction because it has both basement membrane and a collagen matrix that can help to provide resistance to contraction. It is easily harvested, undergoes minimal shrinkage and has a short healing period with no donor site morbidity.

Shield ulcer

Amniotic membrane transplantation combined with surgical debridement is an effective alternative modality in the management of severe shield ulcers (Sridhar M.S et al, 2001). The renewed basement membrane promotes epithelialization, reinforces cellular adhesion and prevents epithelial apoptosis. In 6 (2.84%) eyes with shield ulcer debridement followed by AMT was performed. Resurgery was needed in 1 eye (16.66%). The ulcer healed with disintegration of amniotic membrane within 4-6 weeks. Sutures were removed and BCL wear was discontinued. In cases of severe shield ulcers, in addition to the superficial debridement, the amniotic membrane probably helped by virtue of its antiinflammatory and antiscarring properties and its role as a BCL, all of which promoted healing of the epithelial

defect. (M. S. Sridhar et al, 2001).

Stevens Johnson syndrome

There were 5 eyes (2.36%) with SJS who were managed with topical steroid and lubricating agents before coming to BEH. There was corneal ulcer, conjunctival and lid margin scarring with symblepharon formation in all 5 eyes. Limbus involvement was in 4 eyes. All of them underwent AMT to cover the entire ocular surface from lid margin to lid margin as a temporary biological bandage. The 4 eyes (80%) needed resurgery. Debridement with AMT with CLAU was done. But those cases did not do well. AMT performed in the first two weeks after the onset of ocular involvement facilitates rapid epithelial healing and reduces inflammation and scarring of the ocular surface. Delay in presentation is one of the cause for high failure rate. When performed at a later stage, AMT might still recover the corneal surface, but cannot prevent progressive conjunctival scarring. Therefore, although SJS is relatively rare, the high rate and typically severe ocular morbidity requires prompt diagnosis and early intervention with AMT at the acute stage (Shay E et al, 2009).

PED

There were 4 (1.89%) eyes of PED. In all these cases overlay amniotic graft was performed. After a median follow-up time of 6 months epithelial closure with no recurrence was achieved. AM is used clinically as a basement membrane substitute in patients with PED both with and without corneal ulceration. PED signify varying degrees of LSCD and chronic inflammation. That includes corneal scarring, neovascularization, corneal perforation and loss of the eye. AM serves to provide a basement membrane substrate for the migration and adhesion of epithelial cells when used as an inlay graft as an overlay patch it facilitates epithelialization in a fashion akin to a BCL and by providing a barrier



against inflammatory cells and mediators. The AM, being continuously moistened by tears, provides adequate hydration to the regenerating epithelium and protects it from the abrasive effect of an abnormal palpebral conjunctiva. (Baum J, 2002)

Corneal degeneration

There were 1 eye with BSK and 1 eye with Saltzman's nodular degeneration of cornea that underwent superficial keratectomy with AMT. Postoperatively, subjective relief of preoperative watering, irritation due to the corneal degeneration was achieved in all cases.

Dry eye

There were 2 (0.94%) eyes of severe dry eye with keratopathy in which AMT trial was done. In both cases dry keratinized tissues were removed from cornea, limbus and perilimbal area and overlay amniotic membrane graft was performed. In one case re-surgery was performed with AMT and CLAU for graft rejection. Both cases did not do well and cornea, limbus and conjunctiva were keratinized again in 3 months post-operative period. Amniotic membrane transplantation is a substrate transplantation and thus cannot be used to treat ocular surface disorders that are characterized with a total loss of limbal epithelial stem cells or conjunctival epithelial stem cells. Because amniotic membrane transplantation still relies on the host tissue to supply epithelial and mesenchymal cells, it cannot be used to reconstruct the ocular surface that has severe aqueous tear deficiency, diffuse keratinization (Tseng SCG, 2001).

Bullous keratopathy

There was 1(0.47%) eye of bullous keratopathy. That was a case of pseudophakic bullous keratopathy. The epithelial defect created and covered by AMT healed rapidly within 4-6 weeks. After the AMT patient was comfortable, pain was completely abolished. There was no recurrence in this group. AMT

may also be performed as a temporary measure in patients waiting for corneal transplantation and intolerant to bandage contact lens (BCL). However, long-term relief from AMT needs to be studied and compared with other modalities.

AMT with limbal autograft

In this series there were 189 (89.57%) eyes that underwent AMT and 22 (10.42%) eyes underwent AMT with CLAU for associated limbal stem cell deficiency. That included 5 symblepharon, 9 pterygium, 7 lime and 1 acid injury all of them had limbus involvement. In mild to moderate burns, AMT alone rapidly restores both corneal and conjunctival surfaces. In severe burns without symblepharon, it restores the conjunctival ocular surface and reduces limbal stromal inflammation, but does not prevent limbal stem cell deficiency. This requires further limbal stem cell transplantation. Tseng et al, (1998) reported that use of AMT was beneficial to restore the ocular surface in patients with partial limbal stem cell deficiency, but in severe deficiency associated limbal and amnion transplantation was required.

Complication

In our study we have experienced recurrence of symblepharon (7, 12.28%), pterygium (3, 3.33%), shield ulcer (1, 16.66%). Resurgery was done in 18cases (7adult, 11 pediatrics) including all cases of recurrence with lime injury (1, 4.54%), dry eye (1, 50%) and socket reconstruction (1, 11.11%). Recurrence rate was more in cases with pterygium excision with AMT in comparison to Pterygium extended removal followed by extended conjunctival transplantation (PERFECT). PERFECT is the surgery of choice for pterygium today due to its very low recurrence rate, 1 recurrence in the 1000 surgeries (0.1%) (Hirst LW, 2012).

The other complications like, pyogenic granuloma, iatrogenic microhyphaema (Ma D.H et al, 2000), hematoma formation, microbial infections with use of fresh AM (Khokhar S

et al, 2001), sterile hypopyon after repeated AMT (Gablern et al, 2000), AMG Calcification (Anderson S.B et al, 2003) reported as in other studies were not seen in this series.

Conclusion

Debridement in combination with amniotic membrane graft is an effective surgical modality in the management of ocular surface reconstruction. It could be an ideal graft that is abundant and easily available, without sacrificing the patients' donor tissue. AMT is treatment of choice in eyes where there is no destruction of stem cells but damage of limbal stroma so that cannot support the stem cells as in PUK, pterygium. AMT with CLAU is necessary in eyes with total destruction of limbal stem cell as in chemical injury, SJS. The low rate of intraoperative and postoperative complications and the avoidance of immunosuppression are other advantageous features of this procedure

References

Allen CL, Clare G, Stewart EA, et al (2013). Augmented dried versus cryopreserved amniotic membrane as an ocular surface dressing. *PLoS One*; 8(10): e78441.

Anderson SB, de Souza RF, Hoffmann-Rummelt C, Seitz B (2003). Corneal calcification after amniotic membrane transplantation. *Br J Ophthalmol*; 87(5): 587-591.

Azuara-Blanco A, Pillai CT, Dua HS (1999). Amniotic membrane transplantation for ocular surface reconstruction. *Br J Ophthalmol*; 83:399-402.

Baare VB, Ligtoet EEJ, Middelkoop E (1998). Microbiological evaluation of glycerolized cadaveric donor skin. *Transplantation*; 65 (7): 966-970.

Baum J. Thygeson lecture (2002). Amniotic membrane transplantation: Why is it effective? *Cornea*; 21:339-341.

Bourne GL (1960). The microscopic anatomy of the human amnion and chorion.

Am J Obstet Gynecol; 79:1070-1073.

Cameron PU, Pagnon JC, Van Baare J, Reece CR, Vardaxis NJ, Crowe SM (2000). Efficacy and kinetics of glycerol inactivation of HIV-1 in split skin grafts. *J Med Virol*; 60:182-188.

De Roth A (1940). Plastic repair of conjunctival defects with fetal membrane. *Arch Ophthalmol*; 23:522-525.

Dua H.S, Blanco A.A (1999). Amniotic membrane transplantation. *Br J Ophthalmol*; 83:748-752.

Dua H S, Gomes JAP, King AJ, Maharajan VS. (2004). The Amniotic Membrane in Ophthalmology. *Survey of ophthalmology*; 49 (1): 51-77.

Gabler B, Lohmann CP (2000). Hypopyon after repeated transplantation of human amniotic membrane onto the corneal surface. *Ophthalmology*; 107:1344-1346.

Hirst LW (2012). Recurrence and complications after 1,000 surgeries using pterygium extended removal followed by extended conjunctival transplant. *Ophthalmology*; 119(11):2205-10.

Hook CW, Brown SI, Iwanij W, Nakanishi I (1971). Characterization and inhibition of corneal collagenase. *Invest Ophthalmol*; 10(7): 496-503.

Itoi M, Gnädinger MC, Slansky HH, Freeman MI, Dohlman CH (1969). Collagenase in the cornea. *Exp Eye Res*; 8(3): 369-373.

Khokhar S, Sharma N, Kumar H, Soni A (2001). Infection after use of non preserved human amniotic membrane for the reconstruction of the ocular surface. *Cornea*; 20:773-774.

Kucukerdonmez C, Akova YA, Altinors DD (2007). Comparison of conjunctival autograft with amniotic membrane transplantation for pterygium surgery: surgical



and cosmetic outcome. *Cornea*; 26(4): 407-413.

Lee-Wing MW (2003). Amniotic membrane for repair of exposed hydroxyapatite orbital implant. *Ophthal Plast Reconstr Surg*; 19:401-402.

Ma DH, See LC, Liao SB, Tsai RJF (2000). Amniotic membrane graft for primary pterygium: comparison with conjunctival autograft and topical mitomycin C treatment. *Br J Ophthalmol*; 84:973-978.

Maral T, Borman H, Arslan H, Demirhan B, Akinbingol G, Haberal M (1999). Effectiveness of human amnion preserved long-term in glycerol as a temporary biological dressing. *Burn*; 25(7): 625-635.

Marshall L, Ghoshz MM, Boyce SG, Mac NS, Freedlander E, Kudesia G (1995). Effect of glycerol on intracellular virus survival: implications for the clinical use of glycerol-preserved cadaver skin. *Burns*; 21:356-361.

Meller D, Pires RT, Mack RJ, et al (2000). Amniotic membrane transplantation for acute chemical or thermal burns. *Ophthalmology*; 107(5): 980-989.

Shay E, Kheirkhah A, Liang L, Sheha H, Gregory DG, Tseng CG (2009). Amniotic membrane transplantation as a new therapy for the acute ocular manifestations of Stevens-Johnson syndrome and toxic epidermal necrolysis; 54(6):686-696.

Slansky HH, Gnädinger MC, Itoi M, Dohlman CH (1969). Collagenase in corneal ulceration. *Arch Ophthalmol*; 82(1):108-111.

Sorsby A, Haythorne J, Reed H (1947). Further experience with amniotic membrane grafts in caustic burns of the eye. *Br J Ophthalmol*; 31:409-418.

Sorsby A, Symons HM (1946). Amniotic membrane grafts in caustic burns of the eye. *Br J Ophthalmol*; 30:337-345.

Sridhar MS, Sangwan VS, Bansal AK, Rao GN (2001). Amniotic membrane transplantation in the management of shield ulcers of vernal keratoconjunctivitis. *Ophthalmology*; 108: (7): 1218-1222.

Stewart JM, David S, Seiff SR (2002). Amniotic membrane graft in the surgical management of cryptophthalmos. *Ophthal Plast Reconstr Surg*; 18: 378-380.

Tseng SCG (2001). Amniotic membrane transplantation for ocular surface reconstruction. *Bioscience report*; 21:4.

Tseng SCG, Prabhasawat P, Barton K (1998). Amniotic membrane transplantation with or without limbal allografts for corneal surface reconstruction in patients with limbal stem cell deficiency. *Arch Ophthalmol*; 116: 431-441.

Tseng SCG, Prabhasawat P, Lee SH (1997). Amniotic membrane transplantation for conjunctival surface reconstruction. *Am J Ophthalmol*; 124: 765-774.

Wolbank S, Hildner F, Redl H, van Griensven M, Gabriel C (2009). Impact of human amniotic membrane preparation on release of angiogenic factors. *J Tissue Eng Regen Med*; 3(8): 651-654.

Source of support: nil. Conflict of interest: none